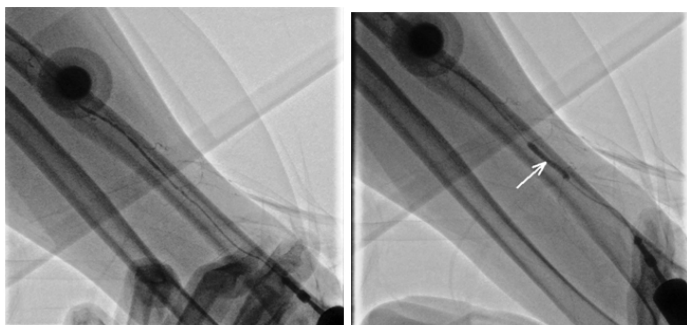


Pseudo-ballooning of Radial Artery- An Artifact

SURENDER DEORA¹, SANJAY SHAH², TEJAS PATEL³**Keywords:** Focal relief, Spasm, Transradial approach

Transradial approach (TRA) for coronary intervention is rapidly increasing worldwide and therefore novel difficulties and complications are frequently observed. Most of these difficulties and complications can be dealt with new techniques and the procedure can be completed through the same artery and seldom needs change to femoral artery approach [1]. Among the various difficulties encountered through TRA, radial artery spasm either focal or diffuse is common and is observed in 14.7% of the cases [2]. Mostly the spasm is relieved completely by spasmolytic cocktails. Here, we describe a very unusual behavior of the radial artery where diffuse spasm was relieved only in the focal segment in spite of repeated spasmolytic cocktail.

A 64-year-old hypertensive female presented with chest pain of 6 hours duration. She had significant past history of ischemic heart disease and underwent percutaneous coronary intervention (PCI) from right radial approach in left anterior descending coronary artery (LAD). A 12-lead electrocardiogram revealed no significant ST-T changes. Transthoracic echocardiography revealed mild left ventricular systolic dysfunction (LVEF ~ 40%). After informed consent, coronary angiography was planned through left radial approach as right radial artery was occluded because of the previous procedure. Left radial artery was punctured successfully but 0.025" hydrophilic wire as well as floppy-tipped 0.014" percutaneous transluminal coronary angioplasty (PTCA) wire could not be negotiated. Injection with diluted contrast through the cannula revealed diffuse spasm of the left radial artery [Table/Fig-1]. As a part of our protocol, 200 mcg of nitroglycerine and 5 mg of diltiazem was administered through the cannula but the radial spasm was not relieved, therefore the spasmolytic cocktail was repeated after 3 minutes. Contrast injection after second spasmolytic cocktail showed focal relief of diffuse spasm presenting an interesting image of 'pseudoballooning' of radial artery mimicking inflated PTCA balloon catheter [Table/Fig-2]. Despite administration of spasmolytic cocktail for third time, the diffuse spasm was not relieved and the coronary angiography was completed through femoral approach [Video-1].



[Table/Fig-1]: Diluted contrast injection through the intra-arterial cannula showing diffuse spasm of left radial artery

[Table/Fig-2]: Repeat contrast injection after spasmolytic cocktail showing focal relief (Arrow) of diffuse spasm mimicking "pseudo-ballooning of radial artery"

REFERENCES

- [1] Patel T, Shah S, Pancholy S, Radadiya R, Deora S, Vyas C, et al. Working through complexities of radial and brachial vasculature during transradial approach. *Catheter Cardiovasc Interv.* 2014;83(7):1074-88.
- [2] Kristic I, Lukenda J. Radial artery spasm during transradial coronary procedures. *J Invasive Cardiol.* 2011;23(12):527-31.

PARTICULARS OF CONTRIBUTORS:

1. Assistant Professor, Department of Cardiology, PGIMER Dr RML Hospital, New Delhi, India.
2. Associate professor, Department of Cardiovascular Sciences, Sheth V.S. General Hospital, Smt. N.H.L. Municipal Medical College, Gujarat University, Ahmedabad, Gujarat, India.
3. Professor & Head, Department of Cardiovascular Sciences, Sheth V.S. General Hospital, Smt. N.H.L. Municipal Medical College, Gujarat University, Ahmedabad, Gujarat, India.

NAME, ADDRESS, E-MAIL ID OF THE CORRESPONDING AUTHOR:

Dr. Surender Deora,
Assistant Professor, Department of Cardiology, PGIMER Dr RML Hospital, Baba Khadak Singh Marg,
New Delhi -110001, India.
E-mail : drsdeora@gmail.com

FINANCIAL OR OTHER COMPETING INTERESTS: None.

Date of Submission: **Apr 02, 2015**

Date of Peer Review: **Jun 10, 2015**

Date of Acceptance: **Jun 18, 2015**

Date of Publishing: **Sep 01, 2015**